

Nonmass Lesion on Breast Ultrasound: A Protean Finding

Ma. Theresa Buenaflor and David Elijah Saguil

Women's Health Department – Healthway Cancer Care Hospital, Taguig City, Philippines

Key words: nonmass lesion, breast ultrasound

ISSN 2507-8364 (Online)
Printed in the Philippines.
Copyright© 2026 by Buenaflor and Saguil.
Received: 14 May 2026.
Accepted: 13 June 2026.
Published online first: 25 June 2026.
<https://doi.org/10.21141/PJP.2026.643>

Corresponding author: Ma. Theresa S. Buenaflor, MD
E-mail: buenates2@gmail.com
ORCID: <https://orcid.org/0000-0001-7257-1265>

INTRODUCTION

The 2025 version of the Breast Imaging Reporting and Data System (BI-RADS) has undergone significant structural changes since 2013. Among the notable changes is the inclusion of Nonmass lesion (NML) on breast ultrasound. It is characterized as a discrete finding that is distinctly different from normal tissue but lacks the margins of a mass and cannot be assigned a specific shape.¹

Nonmass lesion was first described in 2004 by the Japanese Association of Breast and Thyroid Sonology and has since undergone multiple classifications by different authors. A recent description by the Japan Society of Ultrasonics in Medicine encompasses the following findings: a hypoechoic area in the mammary gland, duct abnormalities, architectural distortion, multiple small cysts, and echogenic foci without a hypoechoic area.²

Nonmass lesions may be observed when ultrasound is used to further evaluate mammographic findings of asymmetries, suspicious calcifications, and findings of nonmass enhancement on MRI and contrast-enhanced mammogram (CEM).³

NML on ultrasound correlate with more than 50% of developing asymmetries on mammogram;⁴ 21.4% of hypoechoic nonmass lesions or posterior shadowing correlated with architectural distortion.⁵ About 39% of nonmass lesion correspond to nonmass enhancement on MRI.⁶

A nonmass lesion exhibits variable echogenicity and distribution. It may present as duct abnormalities involving single or multiple dilated ducts and may also have associated features such as echogenic foci, architectural distortion, posterior shadowing, or multiple cysts.²

The incidence of nonmass lesions ranges from 1-10%² and may signal malignancy in 6.3 – 54% of cases.⁷

The differential diagnoses of NMLs include benign processes such as fibrocystic changes, inflammation, post-operative scars, and biopsy scars.⁸

Ductal carcinoma in situ (DCIS) and invasive lobular cancer (ILC) comprise the most common malignancies presenting as nonmass lesions.² Twenty five to sixty one percent (25-61%) of DCIS present as NML on ultrasound.⁹ High-grade DCIS comedo type is considered if there is posterior shadowing associated with clumped microcalcifications.¹⁰ Nonmass findings of invasive lobular carcinoma may present as posterior shadowing only or



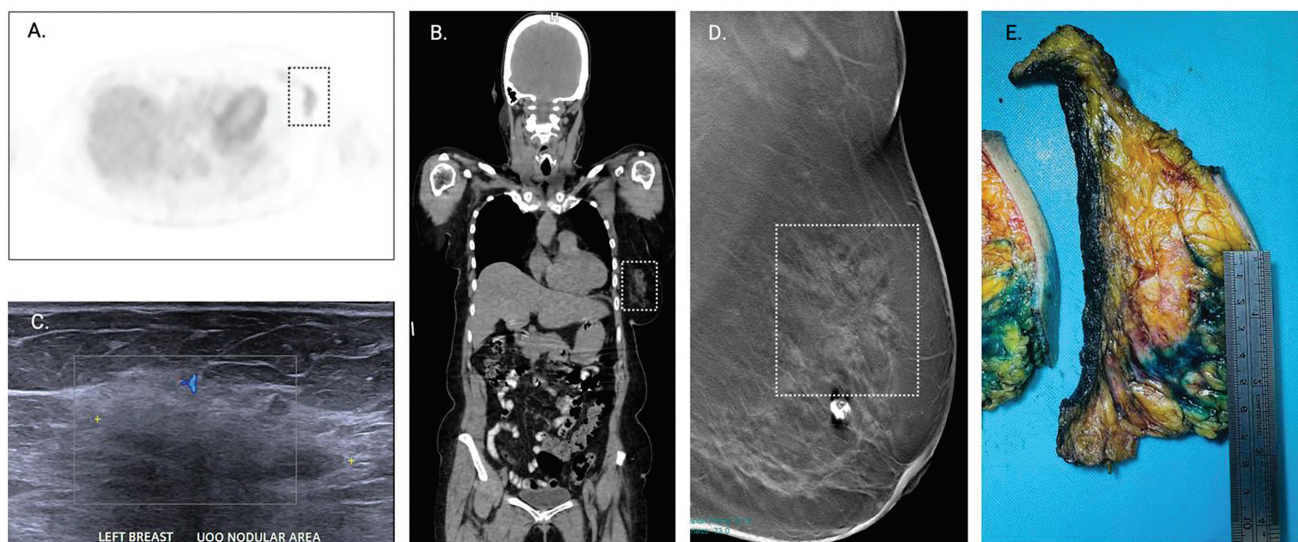


Figure 1. Selected images of her surveillance PET-CT images showed nonmass uptake in the upper outer quadrant of the left breast (A, B) corresponding to a hypoechoic nonmass lesion with shadowing on ultrasound (C). MLO view of her digital breast tomosynthesis (D) demonstrated an architectural distortion (box) at the superior aspect of the left breast. Gross specimen (E) defined the lesion as the inked area.

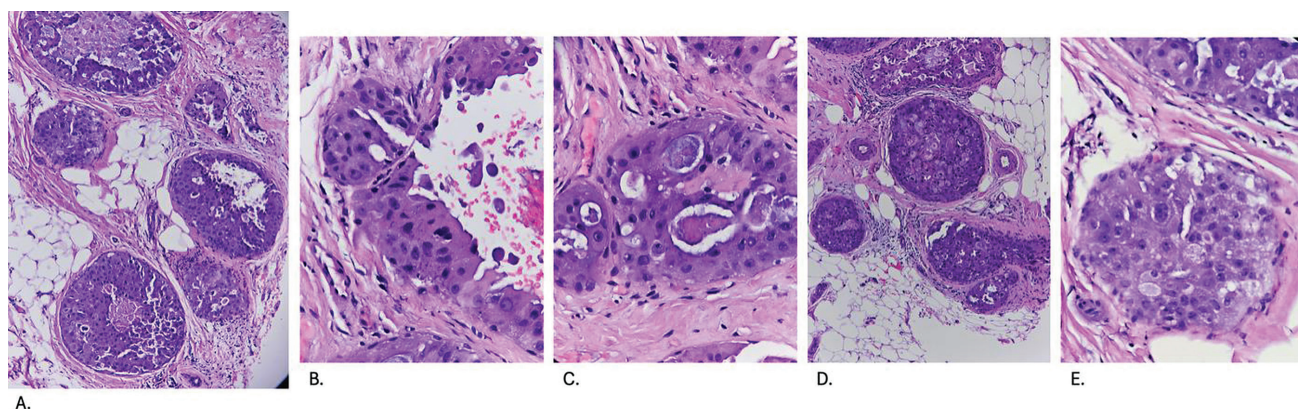


Figure 2. H & E of the needle core biopsy showing high-grade ductal carcinoma in situ (DCIS) on 100x magnification (A) showing comedo (B), cribriform (C), micropapillary (D) and solid (E) patterns.

manifest as hypoechoic inhomogeneous areas consistent with noncohesive and infiltrative growth pattern of ILC.¹¹

LOCAL EXPERIENCE

The first case (Figure 1) demonstrates multimodality imaging findings of a 72-year-old female who is post-mastectomy of the right.

Post-cancer treatment changes and residual lesions after chemotherapy may also present as nonmass lesions (Figure 2).² This represents one of the challenging aspects of breast cancer care.

An example of this is the second case (Figure 3) of a 61-year-old female diagnosed with triple negative breast cancer in the left breast.

Radiologists use the Response Evaluation Criteria in Solid Tumor (RECIST 1.1) to document response to neoadjuvant chemotherapy. Complete response (CR) is defined as

the disappearance of all the target tumors while a partial response (PR) shows at least a 30% decrease in diameter of the tumor.¹²

In a study by Woo et al, radiologic complete response (breast rCR) is defined as disappearance of the breast tumor. If residual disease is observed on follow-up imaging, it is labelled as breast non-rCR.¹³

However, radiologic response is not equivalent to pathologic response. The latter remains as the gold standard in assessing residual tumor burden. In the 8th edition of the American Joint Committee on Cancer (AJCC), tumor size is based on the largest contiguous focus of residual tumor cells, excluding intervening treatment-related fibrosis.¹⁴ It is not the extent of residual tumor foci spanning areas with treatment-related fibrosis.¹⁵

In a study involving one hundred female patients with breast cancer,¹⁶ the prevalent morphological changes after chemotherapy are fibrosis and elastosis/collagenization

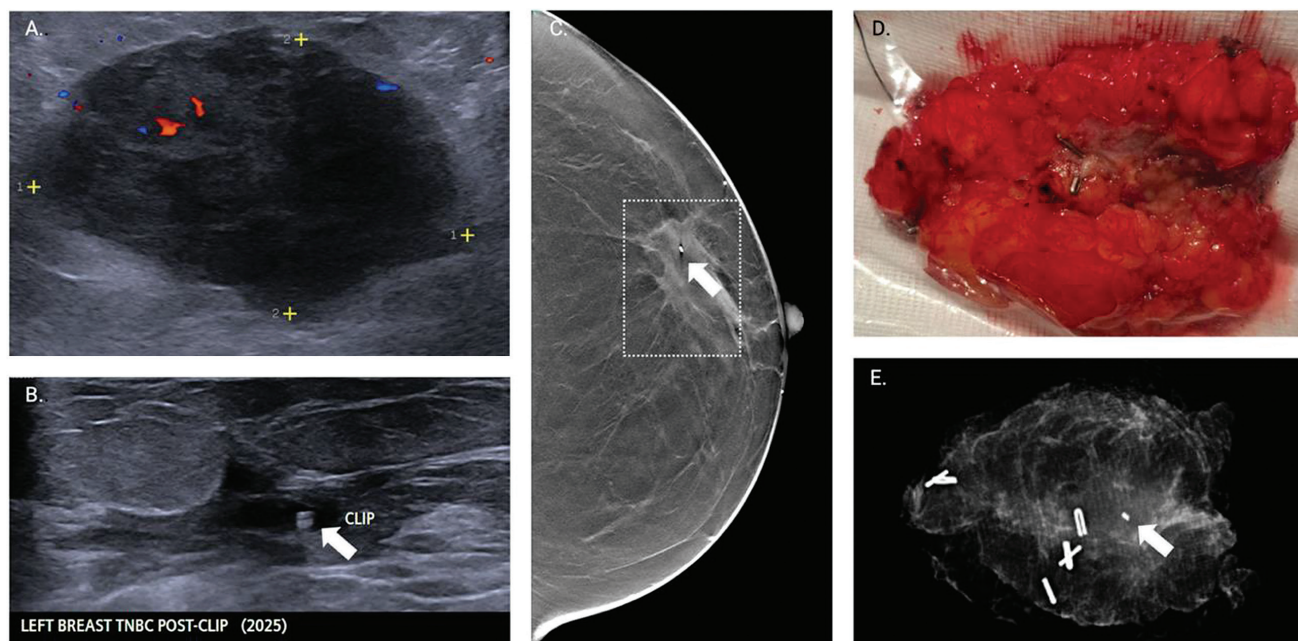


Figure 3. Initial breast ultrasound (A) showed an irregular hypoechoic solid mass prior to clip marking. She underwent neoadjuvant chemotherapy and on follow-up ultrasound (B), a hypoechoic nonmass lesion was now noted with the clip visible (arrow). CC view of her digital breast tomosynthesis (C) showed an asymmetry at the outer left breast. She then underwent partial mastectomy. Gross specimen (D) and the corresponding specimen mammogram (E) showing both the lesion and the metallic clip.

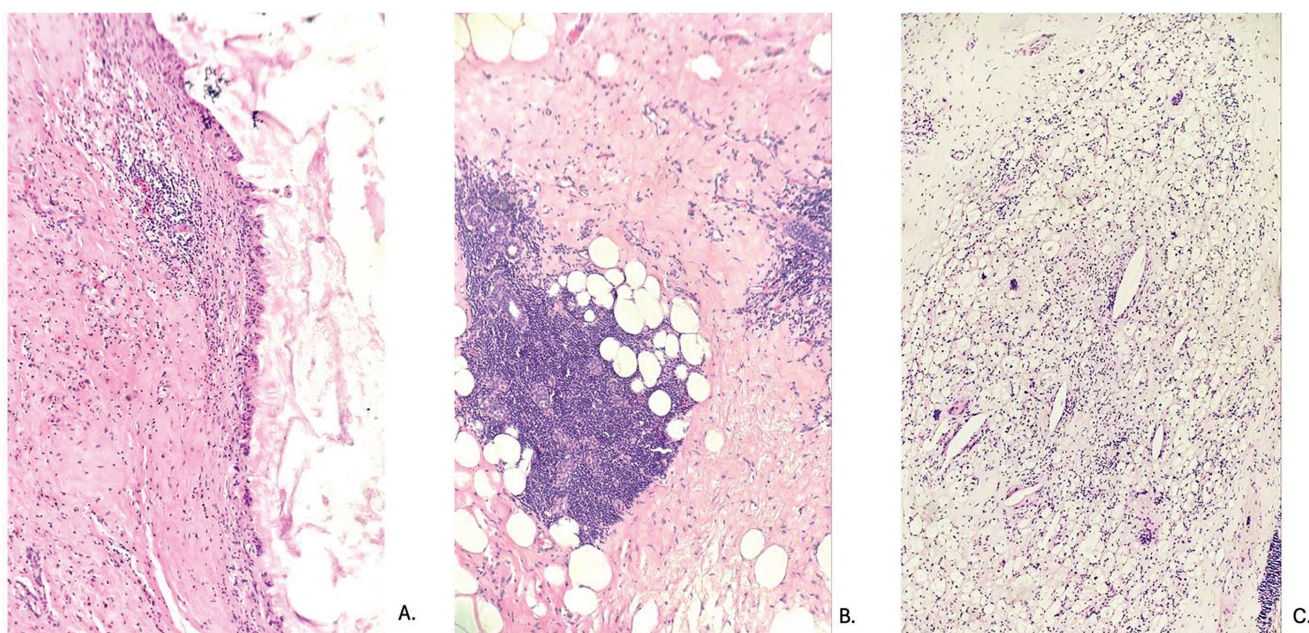


Figure 4. H & E 100x magnification showing (A) the area of the biopsy cavity with inflammation, fibrosis, and cystic contents; (B) shows intralobular stroma with dense lymphocytic infiltration while the interlobular stroma shows fibrosis. Other findings include (C) an area with aggregates of foamy histiocytes with scattered foreign-body type giant cells and cholesterol clefts.

in the stroma. Nuclear alterations are predominantly pyknosis and hyperchromasia.

In the second case, although a nonmass lesion was identified on ultrasound after chemotherapy, the final histopathology showed no residual carcinoma, and findings are illustrated in Figure 4.

DIAGNOSTIC INSIGHT

The management of breast cancer is continually evolving as evidenced by the evolution of its imaging and the emergence of new descriptors such as non-mass lesion on breast ultrasound. A team-based approach with close coordination among clinicians, radiologists and pathologists, is critically integral to optimizing patient care.

CONCLUSION

Cancer is a moving target, and we must not lose sight of it. Although a definitive mass or a protean nonmass lesion may appear at different points of care, as diagnosticians, our common goal remains the same: to identify and characterize it.

ACKNOWLEDGMENTS

The authors extend their thanks to the breast surgeon colleagues from the Women's Health Department, Healthway Cancer Care Hospital, Dr. Aldine Astrid A. Basa, MD, FPCS and Dr. Chris Evert R. Valdez, MD, FPCS.

STATEMENT OF AUTHORSHIP

All authors certified fulfillment of ICMJE authorship criteria.

DATA AVAILABILITY STATEMENT

Datasets generated and analyzed are included in the published article.

AUTHOR DISCLOSURE

The authors have no conflict of interest.

FUNDING SOURCE

None.

REFERENCES

1. American College of Radiology. Breast imaging reporting and data system. Accessed January 5, 2026. <https://www.acr.org/Clinical-Resources/Clinical-Tools-and-Reference/Reporting-and-Data-Systems/BI-RADS>
2. Mohan SL, Dhamija E, Gauba R. Approach to nonmass lesions on breast ultrasound. *Indian J Radiol Imaging*. 2024;34(4):677-87. PMID: 39318554 PMID: PMC11419763 DOI: 10.1055/s-0044-1779589
3. Choi JS, Tsunoda H, Moon WK. Nonmass lesions on breast US: an international perspective on clinical use and outcomes. *J Breast Imaging*. 2024;6(1):86-98. PMID: 38243857 DOI: 10.1093/jbi/wbad077
4. Giess CS, Chesebro AL, Chikarmane SA. Ultrasound features of mammographic developing asymmetries and correlation with histopathologic findings. *AJR Am J Roentgenol*. 2018;210(1):W29-38. PMID: 29064753 DOI: 10.2214/AJR.17.18223
5. Bahl M, Baker JA, Kinsey EN, Ghate SV. Architectural distortion on mammography: correlation with pathologic outcomes and predictors of malignancy. *AJR Am J Roentgenol*. 2015;205(6):1339-45. PMID: 26587943 DOI: 10.2214/AJR.15.14628
6. Sotome K, Yamamoto Y, Hirano A, et al. The role of contrast enhanced MRI in the diagnosis of non-mass image-forming lesions on breast ultrasonography. *Breast Cancer*. 2007;14(4):371-80. PMID: 17986802 DOI: 10.2325/jbcs.14.371
7. Yamaguchi R, Watanabe H, Mihara Y, Yamaguchi M, Tanaka M. Histopathology of non-mass-like breast lesions on ultrasound. *J Med Ultrason* (2001). 2023;50(3):375-80. PMID: 36773105 PMID: PMC10354136 DOI: 10.1007/s10396-023-01286-y
8. Hong S, Li W, Gao L, et al. Diagnostic performance of elastography for breast non-mass lesions: a systematic review and meta-analysis. *Eur J Radiol*. 2021;144:109991. PMID: 34638081 DOI: 10.1016/j.ejrad.2021.109991
9. Jin ZQ, Lin MY, Hao WQ, et al. Diagnostic evaluation of ductal carcinoma in situ of the breast: ultrasonographic, mammographic and histopathologic correlations. *Ultrasound Med Biol*. 2015;41(1):47-55. PMID: 25479813 DOI: 10.1016/j.ultrasmedbio.2014.09.023
10. Gunawardena DS, Burrows S, Taylor DB. Non-mass versus mass-like ultrasound patterns in ductal carcinoma in situ: is there an association with high-risk histology? *Clin Radiol*. 2020;75(2):140-7. PMID: 31739979 DOI: 10.1016/j.crad.2019.10.009
11. Selinko VL, Middleton LP, Dempsey PJ. Role of sonography in diagnosing and staging invasive lobular carcinoma. *J Clin Ultrasound*. 2004;32(7):323-32. PMID: 15293298 DOI: 10.1002/jcu.20052
12. Eisenhauer EA, Therasse P, Bogaerts J, et al. New response evaluation criteria in solid tumours: revised RECIST guideline (version 1.1). *Eur J Cancer*. 2009;45(2):228-47. PMID: 19097774 DOI: 10.1016/j.ejca.2008.10.026
13. Woo J, Ryu J, Jung SM, et al. Breast radiologic complete response is associated with favorable survival outcomes after neoadjuvant chemotherapy in breast cancer. *Eur J Surg Oncol*. 2021;47(2):232-9. PMID: 33213958 DOI: 10.1016/j.ejso.2020.08.023
14. Hortobagyi GN, Connolly JL, D'Orsi CJ, et al. Breast. In: Amin MB, Edge SB, Greene FL, et al, eds. *AJCC Cancer Staging Manual*, 8th ed. Springer; 2017.
15. Harter D, O'Connor SM, Hertel JD, Calhoun BC. Pathological measurement and staging of residual breast cancer after neoadjuvant chemotherapy. *Histopathology*. 2023;83(3):453-64. PMID: 37256703 PMID: PMC10524558 DOI: 10.1111/his.14966
16. Ahuja S, Kiruthikasri G, Zaheer S. Evaluation of histomorphological changes in breast cancer post-neoadjuvant chemotherapy. *Indian J Surg Oncol*. 2024;15(2):236-40. PMID: 38741627 PMID: PMC11088595 DOI: 10.1007/s13193-024-01876-3

Disclaimer: This journal is **OPEN ACCESS**, providing immediate access to its content on the principle that making research freely available to the public supports a greater global exchange of knowledge. As a requirement for submission to the PJP, all authors have accomplished an **AUTHOR FORM**, which declares that the ICMJE criteria for authorship have been met by each author listed, that the article represents original material, has not been published, accepted for publication in other journals, or concurrently submitted to other journals, and that all funding and conflicts of interest have been declared. Consent forms have been secured for the publication of information about patients or cases; otherwise, authors have declared that all means have been exhausted for securing consent.