

# Prevalence and Clinico-Pathologic Features of ALK Rearrangement Among Adult Filipinos with Non-Small Cell Lung Cancer in a Private Tertiary Care Hospital

Steffanie Charlyne Tamayo,<sup>1</sup> Rebecca Nagtalon,<sup>1</sup> Joanmarie Balolong-Garcia,<sup>2</sup> Yancel Donna Mascardo,<sup>2</sup> Jose Jasper Andal,<sup>1</sup> Daphne Ang,<sup>1</sup> Marcelo Severino Imasa,<sup>2</sup> Rex Michael Santiago<sup>1</sup>

<sup>1</sup>Institute of Pathology, St. Luke's Medical Center, Quezon City, Philippines

<sup>2</sup>Section of Medical Oncology, St. Luke's Medical Center, Quezon City, Philippines

## ABSTRACT

**Introduction.** With advancements in the understanding of lung cancer biology, targeted therapy has become the rule rather than the exception. Patients with ALK rearrangements are amenable to therapy with Alectinib and other ALK inhibitors, which has been associated with better patient outcomes. While ALK rearrangement should be routinely tested in non-squamous non-small cell lung cancer (NSCLC), the cost and availability of this test is a prohibitive factor, particularly in the Philippine setting.

**Objectives.** This study aimed (1) to determine the prevalence of ALK-rearranged NSCLC among adult Filipino lung cancer patients in St. Luke's Medical Center (SLMC) from 2016 to 2018 and (2) to determine the clinico-pathologic features of adult Filipinos with ALK-rearranged NSCLC.

**Methodology.** This is a retrospective cross-sectional descriptive study wherein the prevalence of ALK-rearranged NSCLC, detected using fluorescence in-situ hybridization (FISH) or immunohistochemistry (IHC), was determined. Clinical data of patients for whom ALK testing was performed were collected. Hematoxylin and Eosin (H&E) slides were retrieved and reviewed for the presence of certain morphologic features. Patients whose H&E slides cannot be retrieved were excluded from the study.

**Results.** ALK rearrangement was seen in 7.8% (8/103) of tumors submitted for ALK testing. Patients with ALK-rearranged tumors were generally young, light smokers, and presented with advanced clinical stage. Clear cell features and solid pattern were noted in one case and three cases, respectively. However, due to small sample size, further statistical analysis could not be performed to analyze the association of these features with the presence of ALK rearrangement.

**Conclusion.** Despite a small sample size, the prevalence and clinical profile of ALK-rearranged NSCLC in our institution are congruent with those previously described in Western populations. The association of clinical profile and morphologic features with the presence of ALK rearrangement can be further explored in future studies.

*Key words: lung neoplasms, carcinoma, non-small cell lung, anaplastic lymphoma kinase, fluorescence in situ hybridization*

ISSN 2507-8364 (Online)

Printed in the Philippines.

Copyright© 2022 by the PJP.

Received: 11 January 2022

Accepted: 15 March 2022.

Published online first: 5 April 2022.

<https://doi.org/10.21141/PJP.2022.04>

*Corresponding author: Steffanie Charlyne A. Tamayo, MD*

*E-mail: [scatamayo1031@gmail.com](mailto:scatamayo1031@gmail.com)*

*ORCID: <https://orcid.org/0000-0003-2935-4374>*

## INTRODUCTION

As with other malignancies, the stepwise accumulation of oncogenic mutations has been implicated in the pathogenesis of lung cancer. Among the many genetic abnormalities seen in tumor cells, driver mutations are the ones essential for tumor cell survival, a phenomenon called oncogene addiction. Inactivation of these driver mutations are the basis of rational targeted therapy. Prototypical oncogenes in non-small cell lung cancer (NSCLC) include Epidermal Growth Factor Receptor (EGFR), Kirsten Rat Sarcoma Virus (KRAS) and Anaplastic Lymphoma Kinase (ALK). With advancements in the understanding of the biology of lung cancer, these oncogenes have become the object of targeted therapy.

ALK is a receptor tyrosine kinase whose coding gene, which spans 29 exons, is found at chromosome 2p23. The ALK



chromosome encodes a 1,620 amino acid which undergoes post-translational N-linked glycosylation. Normally, ALK is activated by dimerization; this results in auto-phosphorylation of three tyrosine residues. The normal physiologic function of ALK is largely unknown; however, it has been shown to initiate several signal transduction pathways, including the sonic hedgehog pathway, mammalian target of rapamycin, and phosphoinositide 3-kinase/protein kinase B pathway.<sup>1</sup>

ALK mutations in cancer were first identified by Morris et al., in anaplastic non-Hodgkin's lymphoma (ALCL) where a t(2;5)(p23;q35) mutation resulted in a constitutively active ALK kinase.<sup>1</sup> Other malignancies, such as NSCLC, basal cell carcinoma, breast cancer, and colorectal carcinoma, have since been demonstrated to harbor ALK mutations. ALK activation occurs via three different mechanisms: (1) fusion protein formation, (2) ALK over-expression, and (3) activating ALK point mutations.<sup>1</sup> In NSCLC, the most common gene rearrangement is that with Echinoderm Microtubule-associated protein-like 4 (EML4), with the EML4-ALK mutation first being described in NSCLC in 2007. The EML4-ALK fusion is a product of an inversion in the short arm of chromosome 2 which leads to the fusion of the N-terminal domain of EML4 with the intracellular kinase domain of ALK.<sup>1</sup> This results into constitutive tyrosine kinase activity. Aside from EML4, numerous novel fusion partners have also been described as a result of next generation sequencing, including Trafficking from ER to Golgi regulator (TFG), Kinesin Family member 5B (KIF5B), Kinesin Light Chain 1 (KLC1) and Striatin (STRN).<sup>2</sup>

ALK-rearranged NSCLC are usually seen in younger patients who are never or are former/ light smokers. The most common histology is that of an adenocarcinoma with a solid or acinar pattern with focal signet ring cell features.<sup>3,4</sup>

Crizotinib, an orally available aminopyridine-derived small molecule ATP competitive inhibitor, was historically the first ALK inhibitor used clinically in the treatment of NSCLC. It induces a G1/S phase cell cycle checkpoint and apoptosis in ALK-rearranged tumor cells. It has been shown to be superior to standard chemotherapy in patients with previously treated, advanced, ALK-rearranged NSCLC, with noted improvements in response rates and global quality of life.<sup>5</sup> However, next-generation ALK inhibitors with greater systemic and central nervous system penetration and efficacy, such as Alectinib, Brigatinib, and Lorlatinib, are now the first-line treatment options. Among these, Alectinib is preferred due to longer-term follow-up of clinical trials with this agent.<sup>6</sup> Note that prior to targeted therapy, the presence of ALK rearrangements was not a favorable prognostic factor in NSCLC.<sup>1</sup> However, since the Federal Food and Drug Administration (FDA) approval of Crizotinib in 2011, ALK fusion detection is now considered standard of care in lung adenocarcinoma.<sup>7</sup>

Testing for ALK fusion has been facilitated by the commercial availability of a fluorescence in situ hybridization (FISH) assay that uses a dual-labeled "break-apart" probe. FISH is able to accurately and reliably detect all ALK

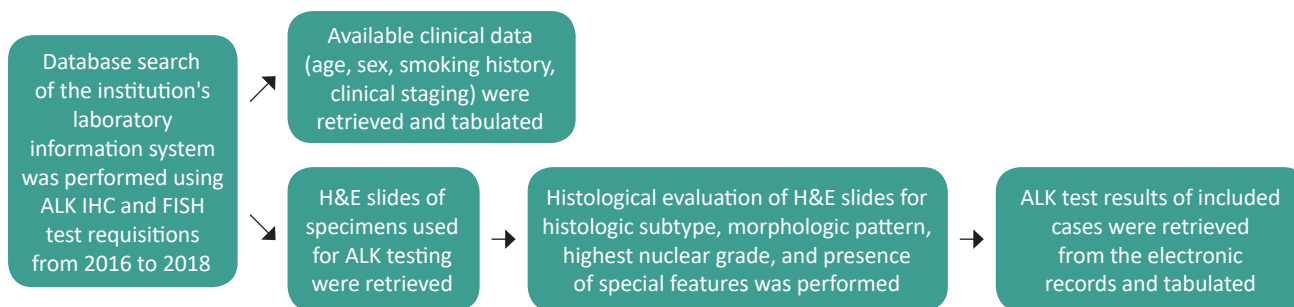
rearrangements regardless of the fusion partner and is thus considered the gold standard for ALK fusion testing.<sup>1</sup> However, it is costly, requires expertise and experience to interpret properly, and often has a lengthy turnaround time. It also requires the presence of a minimum of 50 tumor cells to circumvent false negative results. Other common methods for ALK fusion testing include immunohistochemistry (IHC) and polymerase chain reaction (PCR). IHC has the following advantages: low cost, relative ease of implementation, ease of interpretation, and short turnaround time. While clinical testing for ALK gene rearrangements initially used FISH, the sensitivity and specificity of IHC versus FISH has been found to range from 81% to 100% and current guidelines consider IHC testing (ALK D5F3) as an equivalent alternative to FISH for ALK testing.<sup>8</sup> The high degree of concordance between FISH and IHC has been demonstrated in small biopsy and cytology specimens.<sup>9,10</sup> Currently, there is no recommended minimum number of cells in assessing ALK D5F3 IHC.<sup>11</sup> IHC can therefore be used as an initial standalone test.<sup>12,13</sup> PCR, though specific, sensitive, and less expensive than FISH, misses rare or novel translocations and can have contamination issues. Reverse transcriptase PCR (RT-PCR) is not recommended as an alternative to FISH for detecting ALK rearrangements in NSCLC.<sup>12</sup>

While it is currently part of international guidelines that ALK testing be performed in all patients with non-squamous NSCLC, the cost and availability of this test is a prohibitive factor, particularly in the Philippine setting. As such, this study was undertaken (1) to determine the prevalence of ALK-rearranged non-small cell lung cancer (NSCLC) among adult Filipino lung cancer patients in St. Luke's Medical Center (SLMC) as identified using FISH or IHC done at SLMC and (2) to determine the clinicopathologic features of these adult Filipinos with ALK-rearranged NSCLC.

## METHODOLOGY

This is a retrospective cross-sectional descriptive study wherein the prevalence of ALK-rearranged NSCLC cases identified using FISH analysis (Vysis ALK Break Apart FISH probe kit) or IHC (VENTANA anti-ALK D5F3 rabbit monoclonal primary antibody clone) performed at SLMC from 2016 to 2018 was determined.

A database search of the institution's laboratory information system was performed using ALK IHC and FISH test requisitions from 2016 to 2018. Available clinical data (age, sex, smoking history, and clinical staging) were then collated from the institution's electronic and clinic records. Hematoxylin and Eosin (H&E) slides of the specimens submitted for ALK testing were retrieved and jointly evaluated by two of the authors (one of which is a pulmonary pathology specialist) for the following: histologic subtype, morphological pattern, highest nuclear grade, and presence of signet ring or clear cell features, cribriform pattern, calcification, and necrosis. Specimens for whom the H&E slides cannot be retrieved were excluded from the study. Reports of ALK tests performed on the included cases were then retrieved from the electronic records and tabulated. The study's methodological flowchart is depicted in Figure 1.



**Figure 1.** Methodological flowchart.

ALK, anaplastic lymphoma kinase. H&E, hematoxylin and eosin.

The following operational definitions were used in the study:

- Never smoker – patient who has never smoked or who has smoked less than 100 cigarettes in his or her lifetime
- Light smoker – patient with smoking history less than or equal to ten pack-years<sup>7</sup>
- Heavy smoker – patient with smoking history greater than ten pack-years
- ALK-rearranged – positive for ALK rearrangement
  - Identified using FISH by the presence of broken apart signals, two or more signal diameters apart, in > 50% of at least 50 tumor cells, or in an average of at least 15% of 100 tumor cells
  - Identified using IHC by the presence of strong granular cytoplasmic staining in any percentage of tumor cells
- ALK wild-type – negative for ALK rearrangement
- No special features – NSCLC cases without signet ring cells, clear cells, calcification, necrosis, or cribriform pattern
- Histologic grade cannot be assessed – NSCLC cases where the absence of a definitive morphologic pattern (lepidic, acinar, solid, papillary, and/or micropapillary) precludes assessment of histologic grade

**RESULTS**

Although ALK testing by FISH and IHC are available in our institution, all cases covered by the study period were only submitted for testing by IHC. ALK rearrangement was seen in 7.8% (8/103) of tumors submitted for testing from 2016 – 2018. In the same period, the prevalence of ALK wild type NSCLC was 88.3% (91/103) while indeterminate results were seen in 3.9% (4/103) of cases due to paucity of tumor cells. No equivocal results were noted. The prevalence and clinical features of ALK-rearranged and ALK wild type cases are summarized in Table 1.

Patients with ALK-rearranged tumors had an age range of 31 to 70 years and mean and median ages of 47.3 and 40 years, respectively. Fifty percent (4/8) of these patients were clinically stage IV at the time of ALK testing. Of those with available smoking history, 40% (2/5) were non-smokers while among smokers, 66.7% (2/3) were light smokers. In contrast, ALK wild type tumors affected older patients, with an age range of 32 to 90 years and mean and median ages of 65.9 and 66 years, respectively.

**Table 1.** Clinical features of ALK-rearranged and ALK wild type non-small cell lung carcinoma, retrieved from the institution's electronic and clinic records

	ALK-rearranged (N = 8) N (%)	ALK wild type (N = 91) N (%)
<b>Sex</b>		
Male	5 (62.5%)	54 (59.3%)
Female	3 (37.5%)	37 (40.7%)
<b>Age</b>		
Mean (years)	47.3	65.9
Median (years)	40	66
Range (years)	31-70	32-90
<b>Smoking history</b>		
Non-smoker	2 (25%)	21 (23.1%)
Smoker	3 (37.5%)	24 (26.4%)
Pack-years, mean	10.5	21.9
Pack-years, range	0.5-30	2.25-60
Unknown	3 (37.5%)	46 (50.5%)
<b>Clinical Stage</b>		
IA	0 (0%)	0 (0%)
IB	0 (0%)	1 (1.1%)
II	1 (12.5%)	0 (0%)
IIIA	0 (0%)	1 (1.1%)
IIIB	0 (0%)	0 (0%)
IV	4 (50%)	19 (20.9%)
Unknown	3 (37.5%)	70 (76.9%)

Nearly 21% (19/91) of patients with ALK wild type tumors were clinically stage IV at the time of ALK testing. Of those with available smoking history, 46.7% (21/45) were non-smokers while among smokers, 70.8% (17/24) were heavy smokers. Predominance of male sex was noted in both ALK-rearranged and ALK wild type tumors.

The morphologic features of ALK-rearranged and ALK wild type cases are summarized in Table 2. ALK testing in our institution was performed mostly on cytology specimens. Adenocarcinoma was the most common histologic subtype for both ALK-rearranged and ALK wild type tumors.

Among tumors whose morphological pattern can be definitively assessed, solid pattern was noted in 37.5% of ALK-rearranged tumors compared to 16.5% in ALK wild type tumors. Signet ring cell features, calcification, and cribriform pattern were only noted in ALK wild type tumors. Clear cell features and necrosis were seen in both ALK-rearranged and ALK wild type tumors. However, due to small sample size, further statistical analysis could not be performed to analyze the association



**Table 2.** Morphologic features of ALK-rearranged and ALK wild type non-small cell lung carcinoma

	ALK-rearranged (N = 8)	ALK wild type (N = 91)
<b>Histologic subtype</b>		
Adenocarcinoma	5 (62.5%)	76 (83.5%)
Adenosquamous carcinoma	0 (0%)	1 (1.1%)
Mucinous carcinoma	1 (12.5%)	0 (0%)
Non-small cell lung carcinoma	2 (25%)	9 (9.9%)
Pleomorphic carcinoma	0 (0%)	1 (1.1%)
Others	0 (0%)	4 (4.4%)
<b>Morphological pattern<sup>a</sup></b>		
Lepidic	0 (0%)	2 (2.2%)
Acinar	1 (12.5%)	11 (12.1%)
Solid	3 (37.5%)	15 (16.5%)
Papillary	0 (0%)	8 (8.8%)
Micropapillary	2 (25%)	18 (19.8%)
Cannot be assessed	4 (50%)	64 (70.3%)
<b>Histopathologic grade</b>		
Grade 1	0 (0%)	0 (0%)
Grade 2	0 (0%)	1 (1.1%)
Grade 3	4 (50%)	26 (28.6%)
Cannot be assessed	4 (50%)	64 (70.3%)
<b>Presence of histologic features<sup>a</sup></b>		
Signet ring	0 (0%)	3 (3.3%)
Clear cell	1 (12.5%)	9 (9.9%)
Calcification	0 (0%)	2 (2.2%)
Necrosis	2 (25%)	17 (18.7%)
Cribriform	0 (0%)	5 (5.5%)
No special features	6 (75%)	58 (63.7%)
<b>Specimen type</b>		
Core Biopsy	1 (12.5%)	24 (26.4%)
Cytology	3 (37.5%)	49 (53.8%)
Resection	4 (50%)	18 (19.8%)

<sup>a</sup> Multiple morphological patterns and histologic features were seen in some cases.

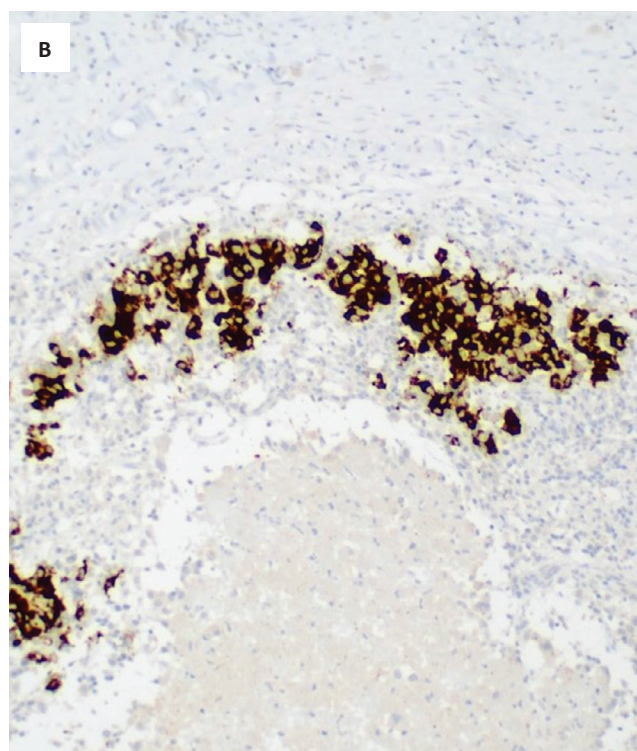
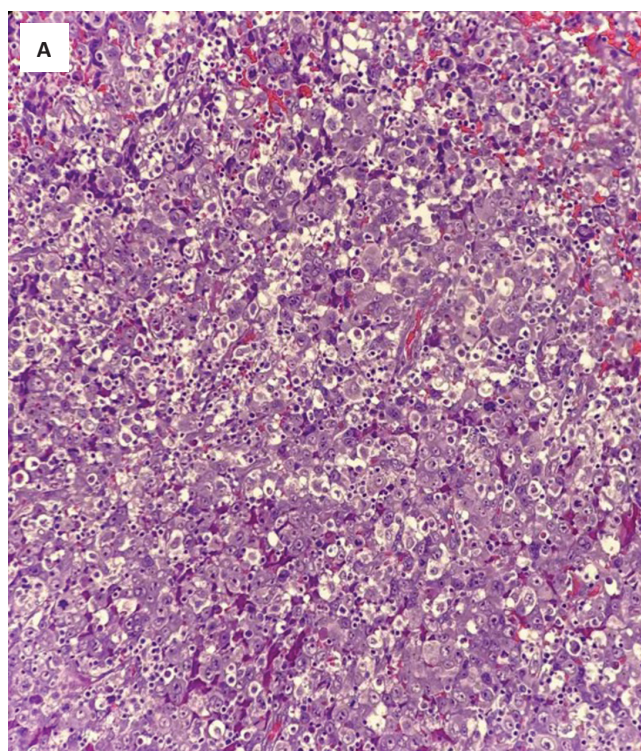
of these features with the presence of ALK rearrangement. A photomicrograph of the only ALK-rearranged tumor with clear cell features is depicted in Figure 2.

### DISCUSSION

Though the sample size for this study is not large enough to perform statistical testing, the results are similar to those previously published in Western journals.<sup>3-5</sup> The prevalence of ALK rearrangement in our institution was not markedly different from previously published rates of ALK rearrangement in NSCLC, which range from 1.5-6.7% in unselected populations and 5% in Asian populations.<sup>2,6</sup> This relative rarity of ALK rearrangement compared to other molecular alterations in NSCLC makes accrual of a large cohort for epidemiologic studies less feasible.

Young age, history of never smoking or light smoking, and high stage disease were previously determined to be statistically different between ALK-rearranged and ALK wild type NSCLC in Western populations; these patterns are also seen in our study. However, it is important to note that these clinical features by themselves are not deemed sufficient to predict the presence of ALK rearrangement with a high degree of certainty.

Early studies also suggested the presence of unique histomorphologic features in ALK-rearranged tumors. These studies evaluated the possible association of the presence of signet ring cells, clear cells, hepatoid cytology, extracellular mucin, calcification, necrosis, and cribriform



**Figure 2.** (A) Non-small cell lung carcinoma with clear cell features and solid pattern (H&E, 20x). (B) The same tumor demonstrating positivity for ALK on immunohistochemistry (ALK IHC, 20x).

pattern with ALK rearrangement. Of these, solid pattern and the presence of signet ring cells were consistently identified as an associated feature.<sup>3,4</sup> In the study by Rodig et al., a solid pattern of growth and the presence of signet ring cells comprising at least 10% of a tumor were noted in 56% of ALK-rearranged cases, compared to only 5% of ALK wild type cases. Nishino et al., likewise noted that a solid-predominant pattern and signet ring cells were more common in ALK-rearranged primary and metastatic lung tumors. Hepatoid morphology and the presence of psammoma bodies/ calcifications were also noted to be more common in primary, but not metastatic, lung tumors.<sup>4</sup> In specimens obtained by minimally invasive procedures (e.g., endobronchial and transthoracic biopsies, core biopsies, and cell blocks), the presence of signet ring cells was the only significant morphologic feature in ALK-rearranged tumors. In our study, although three of the eight ALK-rearranged tumors showed a solid pattern of growth, none of these showed signet ring cell features. Given our small number of ALK-rearranged cases, we could not conclude whether this difference is due to the small sample size, or whether other factors, such as regional differences and the type of specimen (predominantly cytology samples), could have played a role in the discrepancy. Further studies with a larger sample size are needed for a more thorough evaluation of the association between morphologic features and ALK rearrangements.

There has been a push for correlation with clinical profiles and establishment of a scoring system to efficiently triage tumors for ALK rearrangement studies in financially constrained settings. Nishino et al., have proposed one such scoring system, with a sensitivity of 89% and specificity of 75% in their study which included 226 primary lung tumors. Upon validation with a new cohort of 78 lung adenocarcinoma cases, their scoring system was noted to predict ALK rearrangement with a sensitivity of 88%, specificity of 45%, positive predictive value of 49%, and negative predictive value of 87%. However, the authors have recognized that this scoring system will not detect a minority of ALK-rearranged lung tumors and overall do not recommend morphologic analysis alone to screen for ALK rearrangements, since all of these patients are expected to benefit greatly from targeted therapy. In the Philippine setting, where the financial capabilities of the patient are always taken into consideration, it may be worthwhile to further explore morphologic screening for ALK-rearranged tumors in future studies. Until then, the lack of demonstrable correlation between ALK rearrangement and clinico-pathologic features supports the recommendation to test all primary lung adenocarcinomas and non-small cell lung carcinomas/squamous cell carcinomas from never smokers.

## CONCLUSION

Despite a small sample size, the prevalence and clinical profile of ALK-rearranged NSCLC in our institution are congruent with those previously described in Western populations. The association of clinical profile and morphologic features with the presence of ALK rearrangement can be further explored in future studies.

## STATEMENT OF AUTHORSHIP

All authors certified fulfillment of ICMJE authorship criteria.

## AUTHOR DISCLOSURE

The following authors disclosed having a compensated consultant/advisory role: Dr. Jose Jasper Andal for AstraZeneca and Roche; Dr. Rex Michael Santiago for AstraZeneca, Boehringer Ingelheim and Roche.

## FUNDING SOURCE

None.

## REFERENCES

1. Shackelford RE, Vora M, Mayhall K, Cotelingam J. ALK-rearrangements and testing methods in non-small cell lung cancer: a review. *Genes Cancer*. 2014; 5(1-2):1-14. PMID: 24955213. PMCID: PMC4063252. <https://doi.org/10.18632/genesandcancer.3>.
2. Ou SI, Zhu VW, Nagasaka M. Catalog of 5' fusion partners in ALK-positive NSCLC Circa 2020. *JTO Clin Res Rep*. 2020;1(1):100015. PMID: 34589917. PMCID: PMC8474466. <https://doi.org/10.1016/j.jtocrr.2020.100015>.
3. Rodig SJ, Mino-Kenudson M, Dacic S, et al. Unique clinicopathologic features characterize ALK-rearranged lung adenocarcinoma in the western population. *Clin Cancer Res*. 2009;15(16):5216-23. PMID: 19671850. PMCID: PMC2865649. <https://doi.org/10.1158/1078-0432.CCR-09-0802>.
4. Nishino M, Klepeis VE, Yeap BY, et al. Histologic and cytomorphologic features of ALK-rearranged lung adenocarcinomas. *Mod Pathol*. 2012;25(11):1462-72. PMID: 22743652. <https://doi.org/10.1038/modpathol.2012.109>.
5. Shaw AT, Yeap BY, Mino-Kenudson M, et al. Clinical features and outcome of patients with non-small-cell lung cancer who harbor EML4- ALK. *J Clin Oncol*. 2009;27(26):4247-53. PMID: 19667264. PMCID: PMC2744268. <https://doi.org/10.1200/JCO.2009.22.6993>.
6. Solomon B, Lovly CM. Anaplastic lymphoma kinase (alk) fusion oncogene positive non-small cell lung cancer. *UpToDate*. <https://www.uptodate.com/contents/anaplastic-lymphoma-kinase-alk-fusion-oncogene-positive-non-small-cell-lung-cancer#H3811658068>. Accessed August 29, 2021.
7. Travis WD, Brambilla E, Burke AP, Marx A, Nicholson AG, eds. *Tumours of the lung, pleura, and thymus*. In: WHO classification of tumours, 4th ed, vol. 7. Switzerland: World Health Organization; 2020.
8. Bubendorf L, Lantuejoul S, de Langen AJ, Thunnissen E. Nonsmall cell lung carcinoma: diagnostic difficulties in small biopsies and cytological specimens. *Eur Respir Rev*. 2017;26(144):170007. PMID: 28659503. <https://doi.org/10.1183/16000617.0007-2017>.
9. Minca EC, Lanigan CP, Reynolds JP, et al. ALK Status Testing in Non-Small Cell Lung Carcinoma by FISH

- on ThinPrep Slides with Cytology Material. *J Thorac Oncol.* 2014;9(4):464-8. PMID: 24736067. <https://doi.org/10.1097/JTO.000000000000104>.
10. Oki M, Yatabe Y, Saka H, et al. Feasibility and accuracy of molecular testing in specimens obtained with small biopsy forceps: comparison with the results of surgical specimens. *Respiration.* 2015; 89(3): 235-42. PMID: 25676841. <https://doi.org/10.1159/000369860>.
  11. Uruga H, Mino-Kenudson M. ALK (D5F3) CDx: an immunohistochemistry assay to identify ALK-positive NSCLC patients. *Pharmgenomics Pers Med.* 2018;11:147-55. PMID: 30271189. PMCID: PMC6147206. <https://doi.org/10.2147/PGPM.S156672>.
  12. Lindeman NI, Cagle PT, Aisner DL, et al. Updated molecular testing guideline for the selection of lung cancer patients for treatment with targeted tyrosine kinase inhibitors: guideline from the College of American Pathologists, the International Association for the Study of Lung Cancer, and the Association for Molecular Pathology *J Thorac Oncol.* 2018;13(3): 323-58. PMID: 29396253. <https://doi.org/10.1016/j.jtho.2017.12.001>.
  13. National Comprehensive Cancer Network. Non-small cell lung cancer version 7.2021. <https://www.nccn.org/guidelines/recently-published-guidelines>. Accessed November 28, 2021.

**Disclaimer:** This journal is **OPEN ACCESS**, providing immediate access to its content on the principle that making research freely available to the public supports a greater global exchange of knowledge. As a requirement for submission to the PJP, all authors have accomplished an **AUTHOR FORM**, which declares that the ICMJE criteria for authorship have been met by each author listed, that the article represents original material, has not been published, accepted for publication in other journals, or concurrently submitted to other journals, and that all funding and conflicts of interest have been declared. Consent forms have been secured for the publication of information about patients or cases; otherwise, authors have declared that all means have been exhausted for securing consent.

*Publish in the new PJP.*  
*Visit our website:*  
<http://philippinejournalofpathology.org>