

Autopsy Findings in a Patient with Post-Obstructive Pulmonary Edema

Marissa Krizelda Santos,¹ Ann Margaret Chang,¹ Jimmy Chang²

¹Institute of Pathology, St. Luke's Medical Center, Quezon City, Philippines

²Comprehensive Sleep Disorder Center, St. Luke's Medical Center, Quezon City, Philippines

ABSTRACT

Post-obstructive pulmonary edema (POPE), a form of non-cardiogenic pulmonary edema, is a significant entity in anesthesiology and head/neck surgery. This rapidly developing and life-threatening condition occurs following the relief of the obstruction in the upper airways. This condition has two main categories with distinct etiology. We report the case of a 62-year-old Filipino female who developed POPE after the removal of the endotracheal tube following a routine biopsy of her maxillary mass. Immediately after the removal of the endotracheal tube, she presented with episodes of hypotension and desaturation. Chest x-ray post-re-intubation revealed bilateral lung opacities. The autopsy findings of the respiratory and cardiovascular system are presented.

Key words: sleep apnea, obstructive, pulmonary edema, autopsy

ISSN 2507-8364 (Online)

Printed in the Philippines.

Copyright© 2019 by the PJP.

Received: 6 February 2019.

Accepted: 21 March 2019.

Published online first: 25 March 2019.

<https://doi.org/10.21141/PJP.2019.07>

Corresponding author: Ann Margaret V. Chang, MD

E-mail: amvchang@stluke.com.ph

ORCID: <https://orcid.org/0000-0002-9036-3678>

INTRODUCTION

Post-obstructive pulmonary edema (POPE) is a rare condition that in most cases, is associated with complications of general anesthesia. It is categorized into Type I and Type II.¹ In the Type I setting, post-obstructive pulmonary edema occurs once there is sudden and severe episode of upper airway obstruction, while in Type II, pulmonary edema sets in upon the relief of a chronic obstruction. Post-anesthetic laryngospasm is the most frequent cause of POPE in adults.² It is possible that in our case, both types of POPE were exhibited. The laryngospasm probably developed as an effect of the general anesthesia and the relief of the obstruction during the reintubation represent Type I and Type II POPE, respectively.

CASE

A 62-year-old Filipino female, known diabetic and non-hypertensive, was admitted for routine biopsy of a maxillary mass. She was presenting with progressive nasal congestion and intermittent shortness of breath over the last year. Paranasal sinus Computed Tomography (CT) scan revealed a large enhancing irregular soft tissue mass (9.7x7.8x5.9 cm) centered in the left maxillary region with intranasal extension (Figure 1).

History of loud snoring was also elicited in the patient's medical history but was not thoroughly explored. Consequently, no sleep study was performed prior to the operation.

Pre-operative work-up such as electrocardiogram, chest x-ray and hematological studies were normal. The intraoperative course was unremarkable until the time of extubation, when the patient again was noted with loud snoring and with persistent oxygen desaturation as low as 14-40% for 3 to 5 minutes followed by hypotensive



episodes (blood pressure of 80/40 mmHg). She was reintubated and was given inotropes. She was transferred to the intensive care unit and was managed accordingly. The chest x-ray post-intubation revealed bilateral lung opacities attributed to air-space opacification with no appreciable pneumothorax (Figure 2).

Serum electrolytes and blood urea nitrogen were relatively within normal range, while creatinine and white blood cell counts were elevated (Table 1). Despite continuous medical management, she expired after the 2nd post-operative day and a post-mortem examination was performed.

AUTOPSY FINDINGS

A partial autopsy limited to the thoraco-abdominal organs was performed with the consent of the relatives of the decedent and the findings recorded within the institutions' ethical proceedings for documentation and academic purposes.

The decedent was normocephalic, short-necked with endomorphic body habitus. There was a soft to rubbery ill-defined mass (6 cm in single widest dimension) located in the inferior auricular to lateral neck area diagnosed through biopsy as clear-cell tumor with

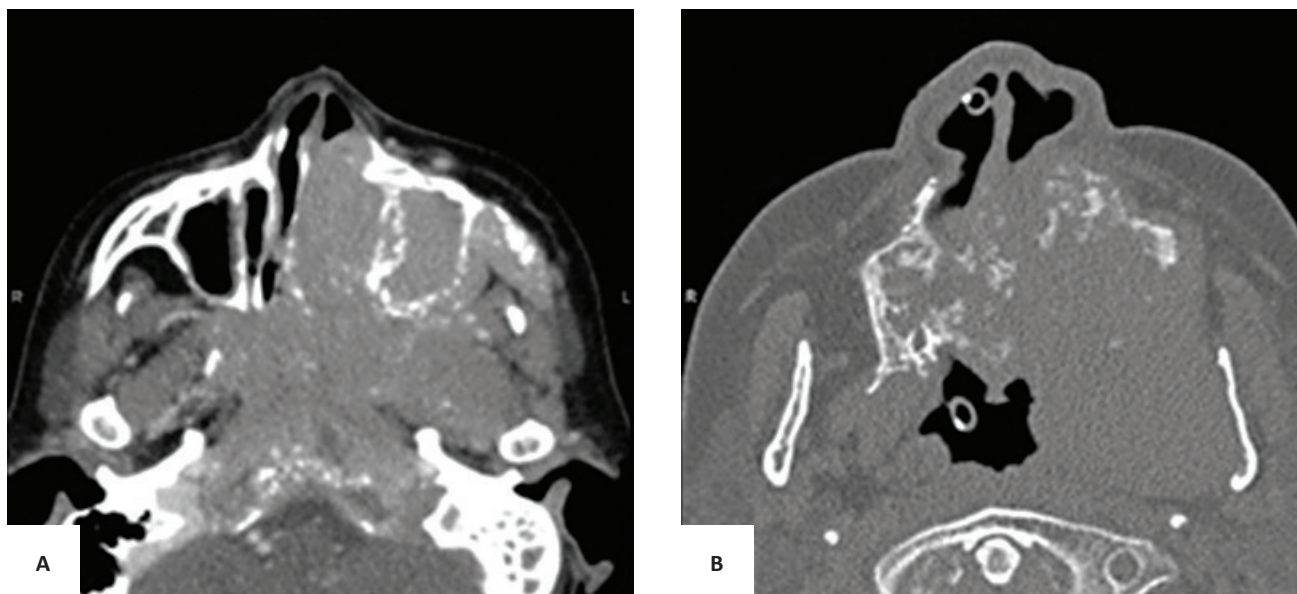


Figure 1. Paranasal Sinus CT Scan after contrast. (A) PNS Axial plane. (B) FESS Axial plane. A large enhancing irregular soft tissue mass lesion (9.7x7.8x5.9 cm) is seen in the left maxillary region extending into the left nasal cavity, left masticator space, left buccal mucosa, both sides of the hard palate, left soft palate, both sides of the nasopharyngeal roof, clivus, both sphenoid sinuses and left posterior ethmoid sinus.

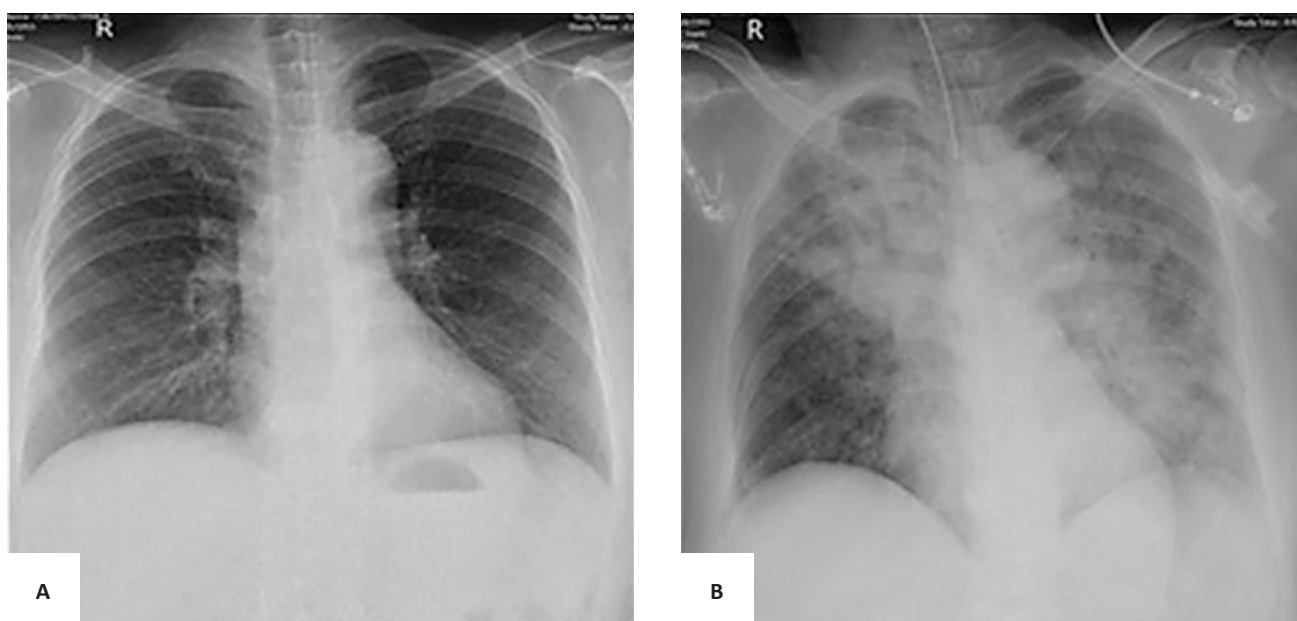


Figure 2. Chest X-Ray. (A) Pre-operative exam showing normal lung parenchyma, normal cardiac silhouette and elongated aorta. (B) Post-operative exam showing bilateral air-space filling opacities.

Table 1. Laboratory results of patient

Analyte	Result	RR	Analyte	Result	RR
Sodium	147	136-145 mEq/L	Hemoglobin	14.7	11.6-15.5 g/dl
Potassium	3.4	3.5-5.1 mEq/L	Hematocrit	46.2	36-47%
Magnesium	2.0	1.8-2.4 mg/dl	RBC	4.59	4.4-5.4x10 ³ /mm ³
Ionized Ca ⁺	1.06	1.09-1.30 mg/dl	WBC	34980	4800-10800 mm ³
Creatinine	1.08	0.55-1.02 mg/dl	Neutrophil	82%	40-74%
Urea	11	7-18 mg/dl	Bands	5%	2-6%
Troponin I	101.9	0-0.30 ng/ml	Lymphocyte	5%	19-48%
INR	1.76	0.9-1.19	Monocyte	8%	3-9%
PT	46.9	29.5-39.9 secs	Platelet	271000	150-400x10 ³ /mm ³

recommendation for immunohistochemical staining for proper histologic classification.

Examination of the head and neck area showed partial left nasal cavity obstruction. No similar obstruction or deformity is noted in the glottis or larynx. The hyoid bone and laryngeal cartilage are normally formed and intact without evidence of fractures or hemorrhage.

A standard Y-shaped thoraco-abdominal incision was done to reveal areas of visceral pleural adhesions in the right lung. Though the weight of the lungs were within normal range (right 750 g; mean reference range, MRR: 185-967 g; left-700 g; MRR: 186-885 grams), frothy material was noted to extrude copiously from both sides (Figure 3A).

Microsections from the bilateral lung lobes showed alveoli filled with red blood cells and proteinaceous material consistent with pulmonary congestion (Figure 3B). There was neither mass on gross examination nor microscopic evidence of carcinomatosis. The major pulmonary vessels and airways were likewise patent and free of any blood clot or emboli.

The heart was normal in size and weight (280 grams). Gross examination of the heart showed no evidence of lesion or old scar (Figure 4). Microsections showed diffuse interstitial fibrosis transecting the myocardial fibers with only focal mild lymphocytic infiltrates. No evidence of infarction was appreciated (Figure 5). The major coronary vessels were patent, thin-walled and devoid of calcifications.

DISCUSSION

Although the Troponin I was elevated, the postmortem examination of our case revealed that the heart was grossly unremarkable. Microscopically, no evidence of myocardial infarction such as myocardial fiber waviness, geographic necrosis nor neutrophilic infiltrates were appreciated. The absence of the microscopic findings of the typical myocardial infarction rules this out as the most likely cause of demise. Instead, diffuse interstitial fibrosis in the absence of cardiac hypertrophy and dilatation are seen transecting the myocardial fibers with only focal, mild lymphocytic infiltrates. Though myocarditis could have resulted in the heart failure as evidenced by the severe pulmonary congestion and edema, cardiomegaly and dilatation of the chambers were not appreciated. Indubitably, cardiac markers remain the cornerstone for the diagnosis of acute coronary syndromes (ACS), although troponin elevation has also been appreciated in non-ACS conditions. A subset of which are seen in patients with chronic airway obstruction and its concomitant negative intrathoracic pressure effect.³ These findings, together with the ventricular tachycardia with limb lead low voltage complexes on the electrocardiogram should elicit a more thorough search for other factors of death causality.

The elevated WBC in our patient in the absence of infection and hematologic disorder are believed to be a secondary reaction to acute lung injury⁴ with neutrophils being elevated in obstructive sleep apnea.⁵

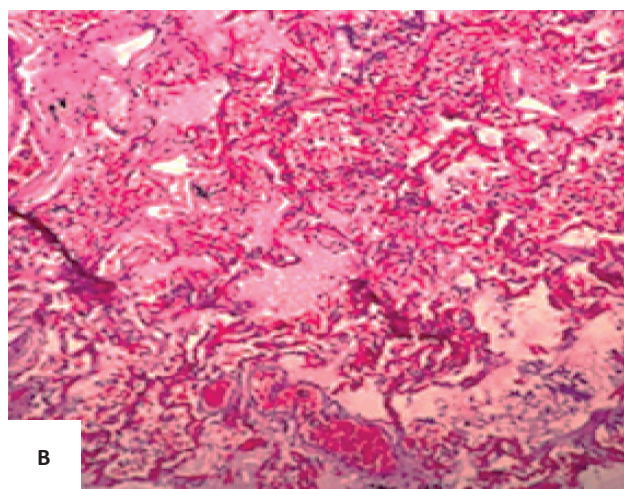
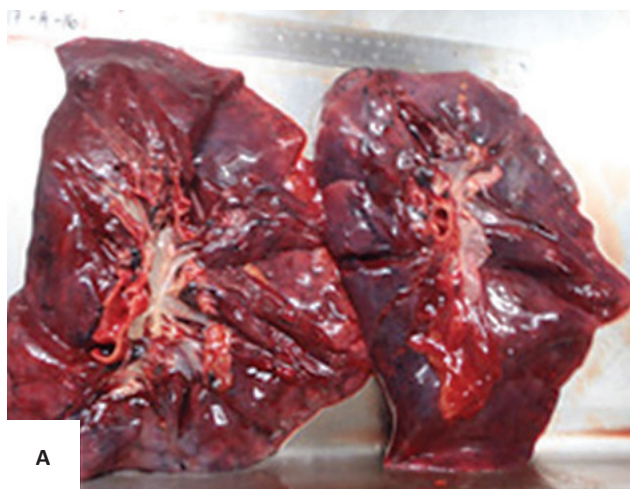


Figure 3. (A) Both lungs were red and appeared heavy grossly. (B) Photomicrograph of lung showing alveoli filled with smooth to slightly floccular pink material and capillaries in the alveolar walls congested with many red blood cells (H&E, 100X).

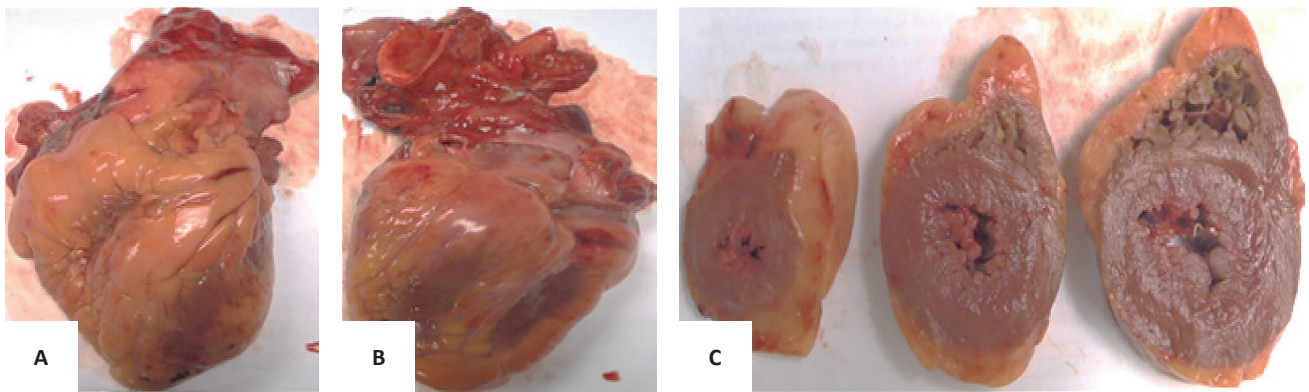


Figure 4. Gross anatomy of heart. **(A)** Anterior view of the heart. **(B)** Posterior view of the heart. **(C)** Cross sections of the heart showed absence of gross lesions and scars.

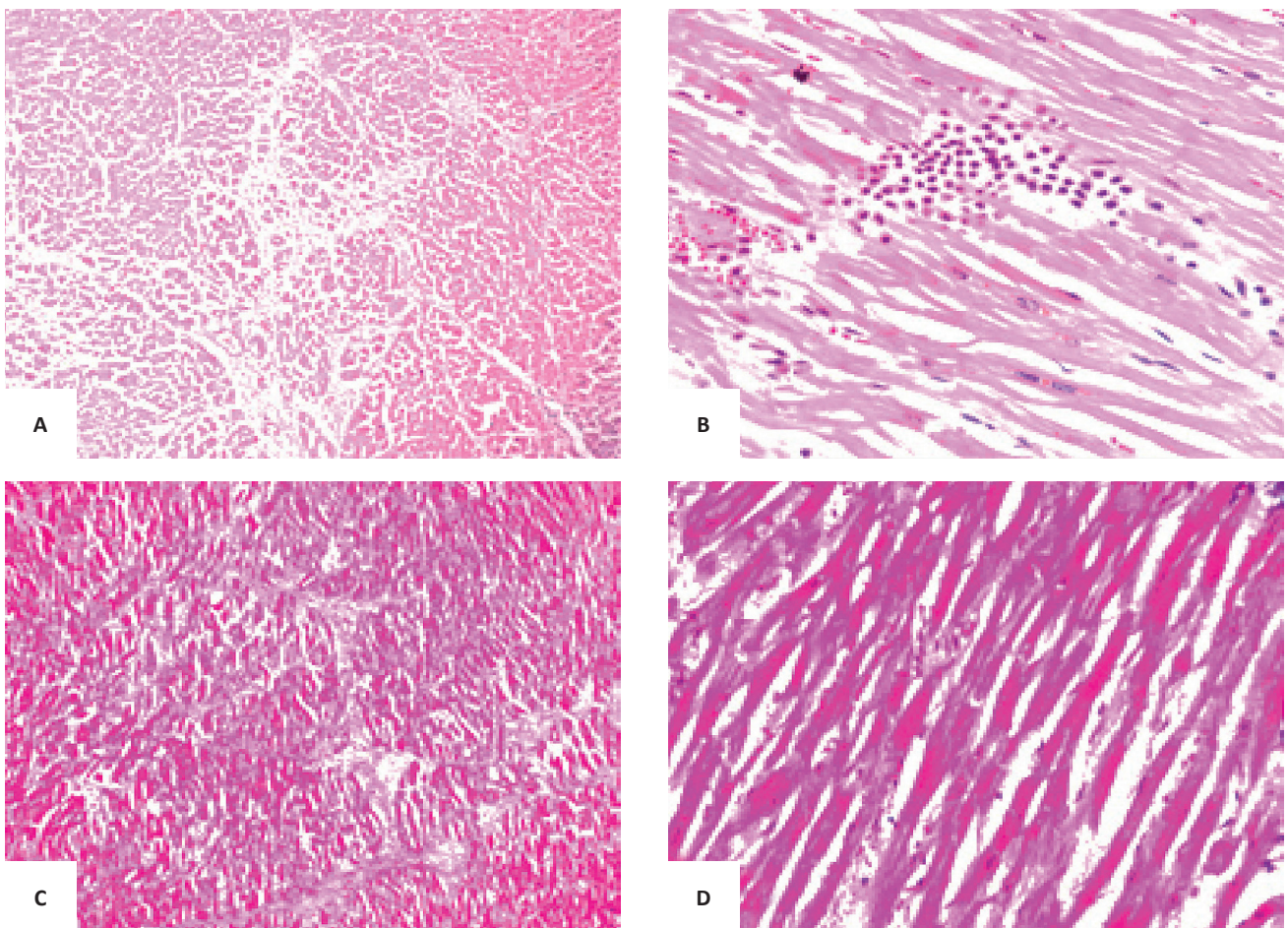


Figure 5. Microsections from the right and left ventricles of the heart. **(A)** Microsections from the left ventricle revealed diffuse interstitial fibrosis transecting the myocardial fibers. **(B)** Microsections from the left ventricle showed focal inflammatory cells which are comprised of lymphocytes. Individual myocardial cell necrosis is also noted. No myocardial fiber waviness and geographic necrosis are appreciated. **(C)** Microsections from the right ventricle also revealed diffuse interstitial fibrosis. **(D)** The presence of mild lymphocytic infiltrates in the left ventricle is appreciated.

The significant gross and microscopic findings in this case are bilateral pulmonary congestion and edema (Figure 3). Based on the CT scan, the patient was noted to have a mass in the left maxillary region which also extends into the left nasal cavity, left masticator space, left buccal mucosa, both sides of the hard palate, soft palate more towards the left side, both sides of the nasopharyngeal roof, clivus, both sphenoid sinuses and left posterior ethmoid sinus. Hence, there was already obstruction in the upper airways. The timeline of the events during the surgical procedure, normal cardiac evaluation, the presence of bilateral pulmonary edema in the absence of any cardiac pathology, favor the diagnosis of post-obstructive pulmonary edema in our case. There are two forms of post-obstructive pulmonary edema. Type I follows a sudden severe episode of upper airway obstruction while Type II develops after surgical relief of chronic upper airway obstruction. In our case, both forms may be present. For the Type I, there is the possibility of post-extubation as well as general anesthesia complications. Based on Ahsayan et al.,⁶ post-obstructive pulmonary edema occurs in 0.1% of all patients undergoing general anesthesia. The patient was noted to have episodes of desaturation after the extubation and this can be attributed to several causes such as the following: laryngospasm, endotracheal tube biting, tongue falling back and extubation before the patient had been sufficiently awakened.^{7,1} On the other hand, the relief of the upper airway obstruction contributes to the development of Type II post-obstructive pulmonary edema. Of note, while patient was still under the effects of anesthesia, she was observed to be snoring loudly. It is possible that aside from the neoplastic obstruction of the upper airway, the patient most likely has undiagnosed obstructive sleep apnea and once she underwent general endotracheal anesthesia, there was transient relief of the upper airway obstruction.

The pathophysiology of post-obstructive pulmonary edema is multifactorial. Initially there is a decrease in interstitial pressure favoring transudation. Alveolar membrane injury can occur sequentially which may consequently result in more transudation. Physiological positive end-expiratory pressure (PEEP) from the obstructed airway counterbalances this positive intravascular pressure, but when relieved of the obstruction, the lack of PEEP permits the transudation of fluid into the alveolar spaces resulting in pulmonary edema. Microscopically, we can appreciate engorgement of the alveolar capillaries as well as the presence of finely granular pale pink material representing the intra-alveolar transudate. The hypoxia from the airway obstruction exacerbates the physiology of post-obstructive pulmonary edema. The hypoxia results in a systemic adrenergic release which then leads to systemic vasoconstriction further increasing venous return. In the lungs, this vasoconstriction further elevates the intravascular pressure thereby encouraging the transudative process.⁸ In chronic airway obstruction, the repetitive chronic negative pulmonary intravascular pressures are counterbalanced by reactive pulmonary vasoconstriction and an increase in pulmonary artery pressure. Eventually, pulmonary hypertension and systemic hypertension develop. Once this occurs, the right-sided heart failure can ensue. In obstructive sleep apnea, the heart also dilates acutely during negative intrathoracic

pressures and systemic blood pressure escalates. The snoring history of the patient and Asian anatomy present an appropriate background for obstructive sleep apnea to confound the already compromised airway. This is why patients with obstructive sleep apnea are at risk for developing POPE after tracheotomy.⁹

CONCLUSION

In a patient with signs of compromised airway, thorough evaluation of compounding factors prior to any procedure should always be performed. Awareness of entities such as post-obstructive pulmonary edema and obstructive sleep apnea may aid in uncovering causes of death. But more importantly, provide an avenue for more stringent pre-anesthetic evaluation to prevent untoward morbidities and mortalities even in seemingly straightforward routine surgical procedures.

ACKNOWLEDGEMENT

The authors acknowledge the invaluable contribution of Dr. Francisco V. Narciso for his heart dissection.

STATEMENT OF AUTHORSHIP

All authors certified fulfillment of ICMJE authorship criteria. All authors have equally contributed to this work, proofread and approved the manuscript for publication.

AUTHOR DISCLOSURE

The authors declared no conflict of interest.

FUNDING SOURCE

None.

REFERENCES

1. Mehta KK, Ahmad SQ, Shah V, Lee H. Postobstructive pulmonary edema after biopsy of a nasopharyngeal mass. *Respir Med Case Rep.* 2015; 16:166-8.
2. Herrick IA, Mahendran B, Penny FJ. Postobstructive pulmonary edema following anesthesia. *J Clin Anesth.* 1990;2(2):116-20. PMID: 2189449.
3. Tanindi A, Cemri M. Troponin elevation in conditions other than acute coronary syndromes. *Vasc Health Risk Manag.* 2011;597-603. PMID: 22102783. PMID: PMC3212425. <https://doi.org/10.2147/VHRM.S24509>.
4. Butt Y, Kurdowska A, Allen TC. Acute lung injury: a clinical and molecular review. *Arch Pathol Lab Med.* 2016;140(4):345-50. PMID: 27028393. <https://doi.org/10.5858/arpa.2015-0519-RA>.
5. Geovanini GR, Wang R, Weng J, et al. Elevations in neutrophils with obstructive sleep apnea: the multi-ethnic study of atherosclerosis (MESA). 2018;257:318-23. PMID: 29506719. PMID: PMC5842816 [Available on 2019-04-15]. <https://doi.org/10.1016/j.ijcard.2017.10.121>.
6. Ahsayan K, Ghalem A, Ouafi NE, Housni B. Post obstructive pulmonary edema: a rare and preventable etiology of postoperative respiratory distress. *J Cardiol*

- Cardiovasc Ther. 2017;6(5):555696. <https://doi.org/10.19080/JOCCT.2017.06.555696>.
7. Granados-Romero J, Valderrama-Treviño AI, Arauz-Peña G, et al. Acute pulmonary non-cardiogenic edema after extubation with laryngospasm: a case report. *Int J Res Med Sci.* 2018; 6(7):2528-32. <https://doi.org/10.18203/2320-6012.ijr.s20182850>.
 8. Lemyze M, Mallat J. Understanding negative pressure pulmonary edema. *Intensive Care Med.* 2014;40(8):1140-3. PMID: 24797685. PMCID: PMC4148265. <https://doi.org/10.1007/s00134-014-3307-7>.
 9. Burke AJ, Duke SG, Clyne S, Khoury SA, Chiles C, Mathews BL. Incidence of pulmonary edema after tracheotomy for obstructive sleep apnea. *Otolaryngol Head Neck Surg.* 2001;125(4):319-23. PMID: 11593165. <https://doi.org/10.1067/mhn.2001.117713>.

Disclaimer: This journal is **OPEN ACCESS**, providing immediate access to its content on the principle that making research freely available to the public supports a greater global exchange of knowledge. As a requirement for submission to the PJP, all authors have accomplished an **AUTHOR FORM**, which declares that the ICMJE criteria for authorship have been met by each author listed, that the article represents original material, has not been published, accepted for publication in other journals, or concurrently submitted to other journals, and that all funding and conflicts of interest have been declared. Consent forms have been secured for the publication of information about patients or cases; otherwise, authors have declared that all means have been exhausted for securing consent.

*Publish in the new PJP.
Visit our website:
<http://philippinejournalofpathology.org>*